

Verrucous Carcinoma of the Penis in a HIV Positive Patient: A Case Report from Nigeria

ANAJE Chetanna Chioma FMCP¹, ENECHUKWU Nkechi Anne FMCP¹,
MENKITI Felix Emeka FMCP², OKPALA Chibuzo Ifeanyi FWACP¹,
NWANKWO Uche Ezekiel FWACS³, EZEJIOFOR Ogochukwu Ifeanyi FMCP¹

¹Department of Medicine, Nnamdi Azikiwe University Teaching Hospital (NAUTH), Nnewi, Anambra State, Nigeria

²Department of Histopathology, NAUTH, Nnewi, Anambra State, Nigeria

³Plastic and Reconstructive Surgery Unit, NAUTH, Nnewi, Anambra State, Nigeria

Corresponding author: Chetanna Anaje. Department of Internal Medicine, Nnamdi Azikiwe University Teaching Hospital, P.M.B. 5001, Nnewi, Anambra State, Nigeria

Email address: chetaobika@yahoo.com, chetaanaje@live.com; **Phone number:** +234 8037756969

Running head: Verrucous cancer of the penis in a Nigerian male

Abstract

Verrucous carcinoma of the penis, a variant of squamous cell carcinoma, is an uncommon urological malignancy. It is characterized by slow growth and presents as exophytic, cauliflower-like masses.

This report describes a case of penile verrucous carcinoma in a 65-year-old HIV-positive male on antiretroviral therapy. He presented with a painful, slow-growing mass on the penile shaft of 9 months duration. Clinical examination showed a cauliflower-like mass on the penile shaft. There was no inguinal lymphadenopathy. Histopathological examination showed epidermal hyperplasia, full-thickness dysplasia, marked hyperkeratosis, and atypical mitotic figures. Surgical excision with the graft was performed, and the patient's condition remained stable.

This case illustrates the potential occurrence of verrucous carcinoma of the penis in the setting of HIV infection, which is a recognized risk factor along with uncircumcised penis, human papillomaviruses, phimosis and others.

Prompt surgical intervention remains the mainstay of treatment for this condition as it offers excellent results. However, given the rarity of this malignancy and the increasing prevalence of HIV, clinicians should maintain a high index of suspicion to facilitate early diagnosis and management, thereby improving patient outcomes.

Keywords: Verrucous carcinoma; Penis; HIV; Nigeria

Carcinome Verruqueux du Pénis chez un Patient Péropositif à Propos d'un cas au Nigéria

Résumé

Le carcinome verruqueux du pénis, une variante du carcinome épidermoïde, est une tumeur maligne urologique rare. Il se caractérise par une croissance lente et se présente sous forme de masses exophytiques en chou-fleur.

Nous rapportons un cas de carcinome verruqueux du pénis chez un homme séropositif de 65 ans sous traitement antirétroviral. Il présentait une masse douloureuse à croissance lente sur la verge depuis 9 mois. L'examen clinique a montré une masse en chou-fleur sur la tige du pénis. Il n'y avait pas d'adénopathie inguinale. L'examen histopathologique a montré une hyperplasie épidermique, une dysplasie de pleine épaisseur, une hyperkératose marquée et des figures mitotiques atypiques. Une excision chirurgicale suivie d'une greffe a été réalisée et l'état du patient est resté stable.

Ce cas illustre la survenue potentielle d'un carcinome verruqueux du pénis dans le cadre d'une infection au VIH, qui est un facteur de risque reconnu au même titre que la non circoncision, les papillomavirus humains, le phimosis etc.

L'exérèse chirurgicale précoce reste le pilier du traitement de cette affection car elle offre d'excellents résultats. Cependant, étant donné la rareté de cette tumeur maligne et la prévalence croissante du VIH, les

cliniciens doivent garder une vigilance élevée pour faciliter un diagnostic et une prise en charge précoces, améliorant ainsi le pronostic des patients.

Mots Clés: carcinome verruqueux ; pénis ; VIH ; Nigéria ; Afrique

INTRODUCTION

Verrucous carcinoma of the penis is a rare urologic malignancy that is slow-growing.¹ The incidence in the United States is less than 1 case per 100,000.² However, in Rwanda, the incidence of penile carcinoma was also low at 0.37 per 100,000.³ In northern Nigeria, specifically Kano, penile cancers accounted for 0.7% of urological cancers.⁴ Risk factors for penile cancers are uncircumcised penis, human papillomaviruses (HPV), human immunodeficiency virus (HIV), poor genital hygiene, phimosis, Bowen's disease, obesity, and smoking.^{5,6} On the other hand, protective factors include circumcision and HPV vaccination.⁵ It presents as a penile mass, which may be painful and rarely metastasizes.

A case of verrucous carcinoma of the penis was reported in the northern part of Nigeria.⁷ There are few case reports of verrucous carcinoma of the penis in HIV-positive patients.^{8,9} The importance of reporting this case is increasing awareness of this uncommon malignancy, which can be misdiagnosed. Herein, we report a case of verrucous carcinoma of the penis in a HIV-positive man.

CASE SYNOPSIS

A 65-year-old male presented with a slow-growing mass on his penis of 9 months duration. The mass was painful but not itchy. He is HIV-positive and was diagnosed 15 years ago. He is currently on tenofovir, lamivudine and efavirenz tablets. On examination of the penis, there was a solitary tumour which measured 3 cm x 4 cm, on the penile shaft close to the head of the phallus. The tumour had a yellowish cauliflower-like surface with creamy exudates on an erythematous background. (Figure 1). There was no inguinal lymphadenopathy. Laboratory tests were routine. The absolute CD4+ T helper cell count for HIV was 525 cells/mm³, and the viral load was <20 copies/ml; however, a polymerase chain reaction test for HPV DNA could not be done in our

facility. Histopathology of a biopsied specimen showed hyperplastic epidermis with full-thickness dysplasia, and the composite cells had grade 3 nuclei and moderate cytoplasm. The base of the inflammation was bulbous, with intense chronic inflammation at the superficial dermis and some atypical mitotic figures. The epidermis was papillomatosis with hyperkeratosis (Figures 2A and 2B). The patient was operated on by the plastic surgeon – wide excision surgery. The patient's post-operative condition remains stable.

DISCUSSION

Verrucous carcinoma of the penis is a rare, well-differentiated variant of squamous cell carcinoma with a slow growth rate. It rarely metastasizes.¹ Ackerman made the first description of verrucous carcinoma in the oral cavity.¹⁰ It has been described in other locations of the body like the penis, female genital tract and sole.¹¹ The prevalence rates of verrucous carcinoma of the penis in Tanzania and Mozambique were 2.1% and 2.4% respectively.^{6,12}

The etiopathogenesis is not fully understood.¹³ Risk factors for this disease include lack of circumcision, phimosis, human papillomaviruses (HPV), human immunodeficiency virus (HIV), history of balanoposthitis or condyloma, obesity, smoking, poor genital hygiene, Bowen's disease, Marjolin's ulcer.^{5,6} Human immunodeficiency virus (HIV) can cause carcinogenesis through the generation of reactive oxygen species, which can induce malignant transformation of epithelial cells.¹⁴ Furthermore, HIV can act synergistically with human papillomavirus (HPV) infection, thereby potentiating carcinogenesis.¹⁴ Interestingly, in this case, the patient had undergone circumcision; however, he was HIV-positive, which is a known risk factor for the development of this malignancy.

Verrucous carcinoma of the penis usually occurs on the glans or foreskin, but it can appear anywhere on the penis.¹⁵ It presents as a cauliflower-like or exophytic mass, which may be malodorous or

ulcerated. It can also present as a cutaneous horn.¹⁶ It tends to develop at sites of chronic inflammation and irritation.⁹ Despite its relatively slow growth, it may be locally destructive, infiltrating deep into the skin, fascia and even bone. It can lead to acute urinary retention.^{8,15}

Our patient's absolute CD4+ T helper cell count for HIV was 525 cells/mm³, in contrast to the 20 cells/mm³ reported by Noronha.⁹ The relatively preserved immune status indicated by our patient's CD4+ T-helper cell count raises the question of how verrucous carcinoma developed despite adequate immune function. Several factors are worth considering. First, although CD4+ counts are a marker of immune competence, qualitative defects in immune function, including impaired cytotoxic T-cell responses, may contribute to oncogenesis.¹⁷ Additionally, there could be concurrent infection with HPV. This case highlights the importance of monitoring HIV-positive patients on anti-retroviral therapy for the development of malignancies, even in those with relatively stable immune function.

Histopathology of verrucous carcinoma of the penis shows massive hyperplasia of the epidermis with marked hyperkeratosis and parakeratosis, acanthosis and anastomosing papillomatosis.¹³ The granular layer is prominent with several vacuolated cells that resemble koilocytes of condyloma acuminatum, and there is the presence of lymphohistiocytic infiltrate.¹³

Differential diagnoses of verrucous carcinoma of the penis are condyloma acuminata, simple verrucous hyperplasia and papillary carcinoma.¹⁸

The primary treatment approach for penile verrucous carcinoma is surgical intervention, typically involving wide excision. Depending on the location and extent of spread, glansectomy or penectomy may be indicated. Such procedures can have a significant impact on the psychosexual aspect. Adjunctive chemotherapy may also be administered as part of the treatment regimen.⁹ Other treatment options are Mohs Surgery, cryosurgery, laser surgery in combination with topical fluorouracil cream and systemic or intralesional interferon and photodynamic

therapy.^{8,19} However, surgery is the preferred treatment modality as it has excellent outcomes.²⁰ Disease recurrence is usually rare if treated surgically.^{1,8,15}

CONCLUSION

This case report contributes to the limited literature in our region and emphasizes the importance of having a high index of suspicion. It highlights the need for clinicians to maintain a high index of suspicion when encountering penile lesions, especially in the context of the rising prevalence of HIV. Increasing awareness is crucial as it will reduce morbidity and improve the outcomes of patients who are affected.

Declaration of patient consent:

The authors certify that they have obtained all appropriate patient consent forms. In the form, the patient consented to his images and other clinical information being reported in the journal. The patient understands that his name and initials will not be published and due efforts will be made to conceal his identity, but anonymity cannot be guaranteed.

Financial support and sponsorship: Nil.

Conflicts of interest: There are no conflicts of interest.

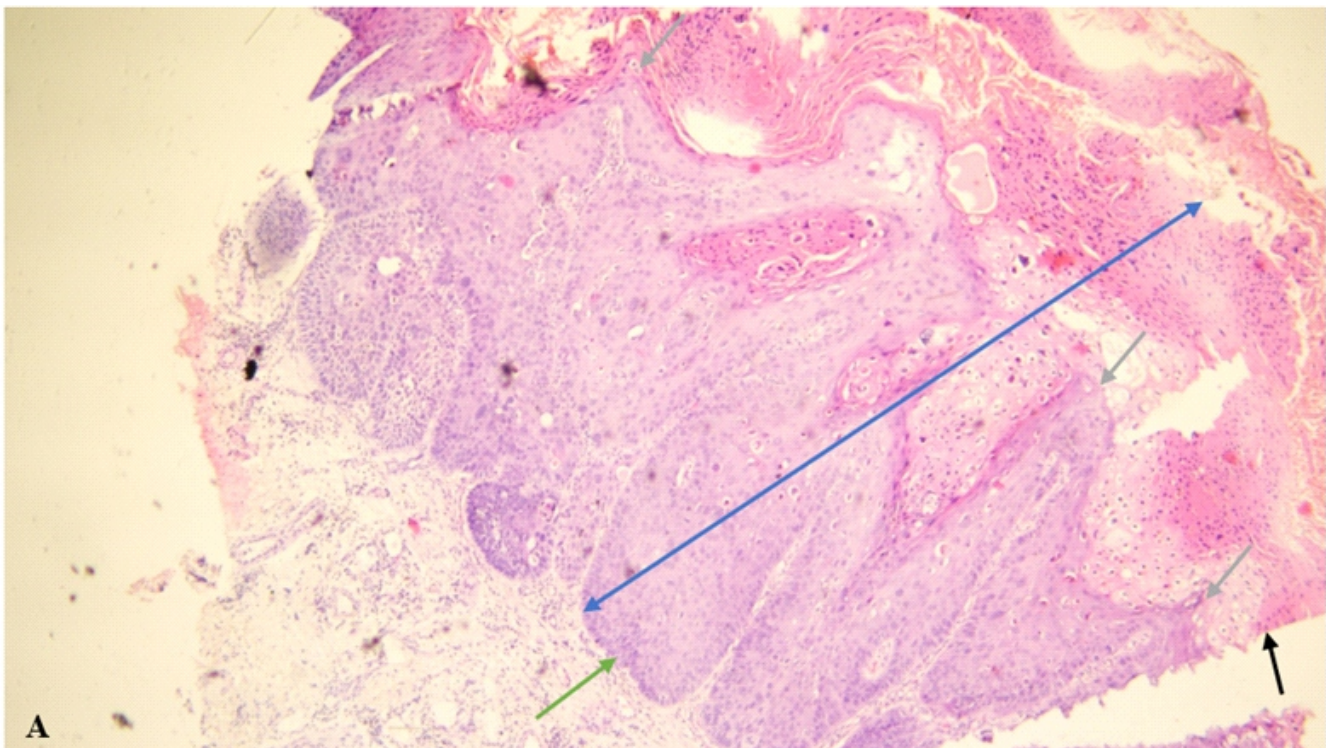
REFERENCES

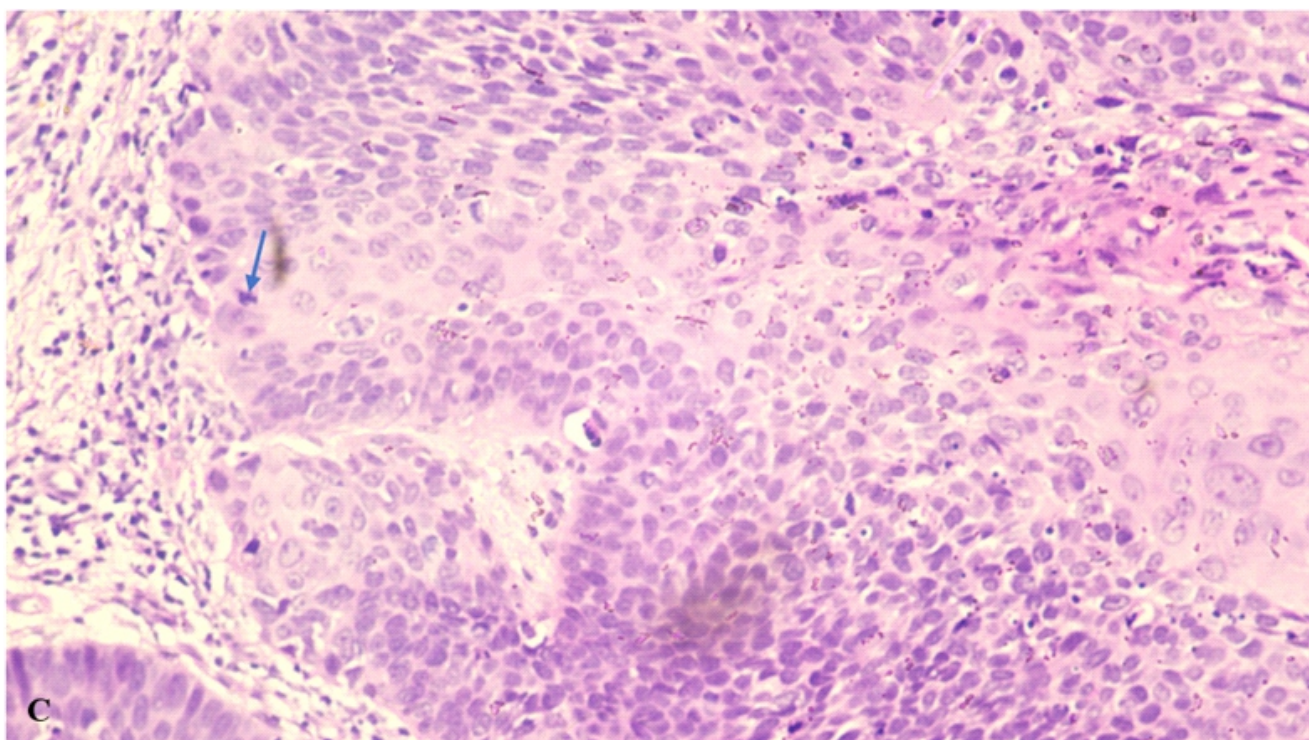
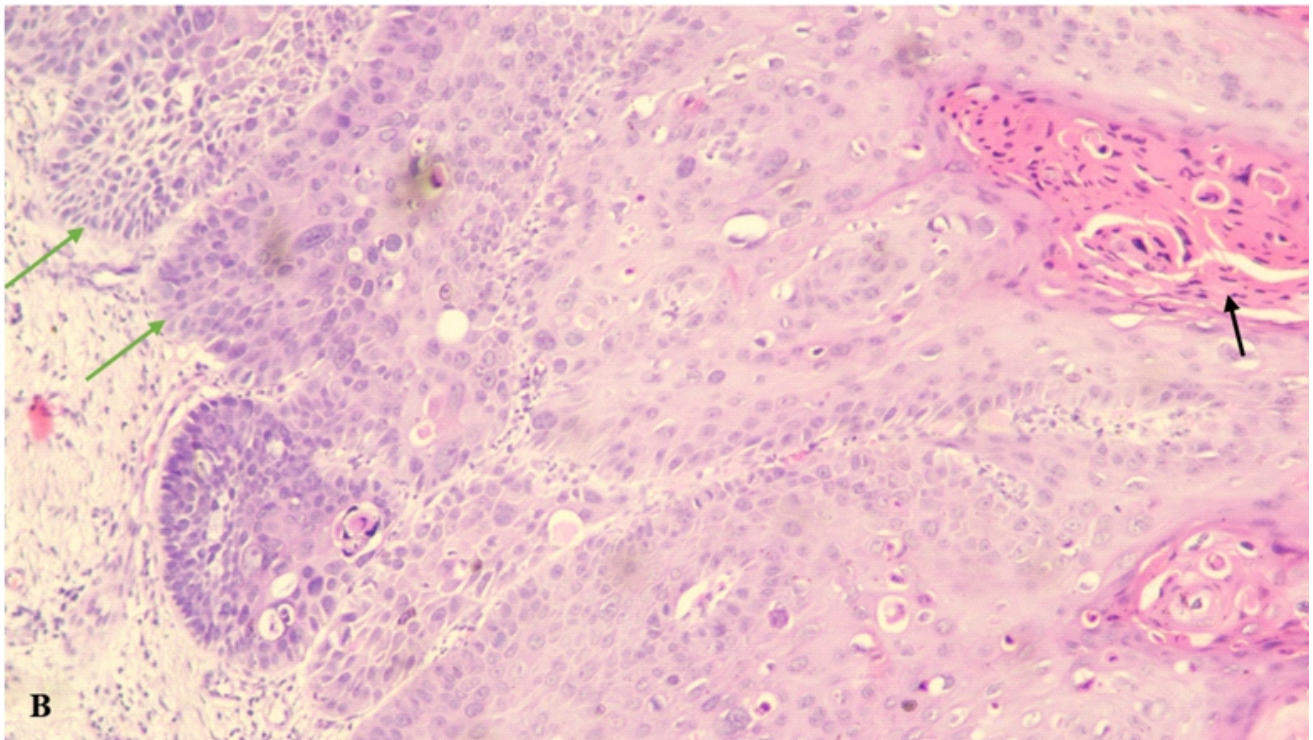
1. Yuksel O, Karabay E, Bilen O, Tosun Ç, Verim L. Penile verrucous squamous cell carcinoma: A rare case report. *Archivio Italiano di Urologia e Andrologia*. 2020 Jun 23;92(2):114–6.
2. Jemal A, Murray T, Ward E, Samuels A, Tiwari RC, Ghafoor A, et al. Cancer Statistics, 2005. *Cancer Journal for Clinicians* [Internet]. 2005;55(1):10–30. Available from: <http://caonline.amcancersoc.org/cgi/content/full/55/>
3. Ngendahayo E, Nzayirambaho M, Bonane A, Gasana GA, Ssebuufu R, Umurangwa F, et al. Pattern and clinical management of penile cancer in Rwanda. *African Journal of Urology*.

- 2018 Dec 1;24(4):274–81.
4. Abdulkadir A, Alhaji S, Sanusi H. Pattern of urological cancers in Kano: North-western Nigeria. *Sub-Saharan African Journal of Medicine*. 2016;3(4):182.
 5. Douglawi A, Masterson TA. Updates on the epidemiology and risk factors for penile cancer. Vol. 6, *Translational Andrology and Urology*. AME Publishing Company; 2017. p. 785–90.
 6. Chalya PL, Rambau PF, Masalu N, Simbila S. Ten-year surgical experiences with penile cancer at a tertiary care hospital in northwestern Tanzania: A retrospective study of 236 patients. *World J Surg Oncol*. 2015 Feb 22;13(1).
 7. Mustapha K, Ajape AA, Khalifa IA, Lawal AI, Arogundade A. Penile Cancers in Gombe: A report of three Cases in 10 years. *Nigerian Journal of Urology* [Internet]. 2022 [cited 2024 Apr 25];10(1 & 2). Available from: <https://nju.org.ng/index.php/nju/article/view/41>
 8. Okieh YA, Tombet CA, El Moudane A, Kouiss Y, Barki A. Surgical Treatment of Penile Verrucous Squamous Cell Carcinoma in an HIV-Infected Patient: A Case Report. *Cureus*. 2023 Apr 18;
 9. Noronha T, Girisha B, Bhat S, Christy C, Handattu S, Fernandes M. A rare case of verrucous carcinoma of penis in an human immunodeficiency virus- infected patient. *Indian J Sex Transm Dis*. 2015 Jul 1;36(2):192–4.
 10. Ackerman L. Verrucous carcinoma of the oral cavity. *Surgery*. 1948;23(4):670–8.
 11. Fawaz B, Vieira C, Decker A, Lawrence N. Surgical treatment of verrucous carcinoma: a review. Vol. 33, *Journal of Dermatological Treatment*. Taylor and Francis Ltd.; 2022. p. 1811–5.
 12. Manzotti C, Chulo L, López del Campo R, Trias I, del Pino M, Saúde O, et al. Penile Squamous Cell Carcinomas in Sub-Saharan Africa and Europe: Differential Etiopathogenesis. *Cancers (Basel)*. 2022 Nov 1;14(21).
 13. Micali G, Nasca MR, Innocenzi D, Schwartz RA. Penile cancer. Vol. 54, *Journal of the American Academy of Dermatology*. 2006. p. 369–91.
 14. Isaguliants M, Bayurova E, Avdoshina D, Kondrashova A, Chiodi F, Palefsky JM. Oncogenic effects of HIV-1 proteins, mechanisms behind. Vol. 13, *Cancers*. MDPI AG; 2021. p. 1–24.
 15. Gîngu C, Turcanu A, Dick A, Crasneanu M, Patrascioiu S, Surcel C, et al. Giant verrucous carcinoma of the penis - case report. *Romanian Journal of Urology*. 2014;13(1):36.
 16. Pai V, Kikkeri N, Shastri U, Sori T. Verrucous carcinoma over the penis presenting as nail-like cutaneous horn. *Clin Cancer Investig J*. 2012;1(1):33.
 17. Perdomo-Celis F, Velilla PA, Taborda NA, Rugeles MT. An altered cytotoxic program of CD8+ T-cells in HIV-infected patients despite HAART-induced viral suppression. *PLoS One* [Internet]. 2019 Jan 1 [cited 2024 Nov 30];14(1):e0210540.
 18. Sujatha S, Kumar VS, Durga K. A five-year study on differential diagnosis of verruciform penile lesions. *International Archives of Integrated Medicine* [Internet]. 2017;4(10):123–7. Available from: <http://iaimjournal.com/>
 19. He X, Zhang J, Tan L, Wang W, Song Y, Wang H, et al. Treatment of verrucous carcinoma in penis with topical aminolevulinic acid photodynamic therapy: An effective and safe treatment method. *Photodiagnosis Photodyn Ther*. 2018 Dec 1;24:232–6.
 20. Chen MF, Chen WC, Wu C Te, Chuang CK, Ng KF, Chang JTC. Contemporary management of penile cancer including surgery and adjuvant radiotherapy: An experience in Taiwan. *World J Urol*. 2004;22(1):60–6.

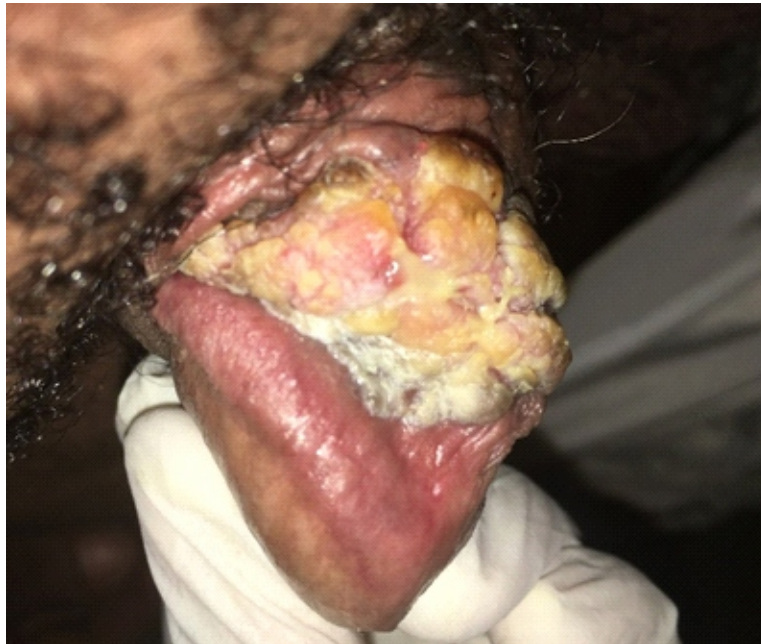

Figure 1: A cauliflower mass on the phallus





Figures 2A-C: Microscopic examination reveals a skin tissue with acanthotic squamous epithelium (double-headed arrow) with full-thickness dysplastic well to moderately differentiated squamous cells having vesicular nuclei and abundant glassy cytoplasm. There are exophytic papillary processes (grey arrows) with overlying hyperkeratosis and parakeratosis (black arrows). Towards the dermis, the dysplastic epithelium shows bulbous pushing borders (green arrows) and superficial dermal chronic inflammation. Some atypical mitotic figures (blue arrow) are observed, but few. (Haematoxylin and Eosin: A=X40; B=X200; C=X400)